

Mechanical thrombectomy in acute occlusion of the carotid T: retrospective single center experience in 51 patients

Daniela Bach¹, Dr. Silke Wunderlich², Dr. Holger Poppert², Dr. Sascha Prothmann¹

¹ Klinikum rechts der Isar Technische Universität München, Neuro-Kopf-Zentrum, Abteilung für diagnostische und interventionelle Neuroradiologie, Ismaninger Str. 22, 81675 Munich
² Klinikum rechts der Isar Technische Universität München, Neuro-Kopf-Zentrum, Neurologische Klinik und Poliklinik, Ismaninger Str. 22, 81675 Munich

P030

47. Jahrestagung der Deutschen Gesellschaft für Neuroradiologie, Köln, 11. - 13. Oktober 2012

Introduction

Acute occlusions of the carotid T are associated with severe syndromes and devastating clinical outcome [1, 2]. Such patients usually have a poor prognosis [3] and a mortality rate up to 40% [2, 4] under conservative treatment. IV thrombolysis was the first approach to eliminate such occlusions but the recanalization rate stays very low with only about 10% [5] and the proportion of patients with good clinical outcome after iv thrombolysis is small [6]. Improvement of the outcomes requires more efficient methods such as clot retrieval therapy [7]. A number of trials concerning EMT with different thrombectomy devices were made. But there are still few data about the clinical outcome and no sufficient comparative data about the devices. In this retrospective study we analyzed 51 patients with an occlusion of the carotid T which were treated with Endovascular Mechanical Thrombectomy (EMT) and data was collected about the clinical outcome.

Methods

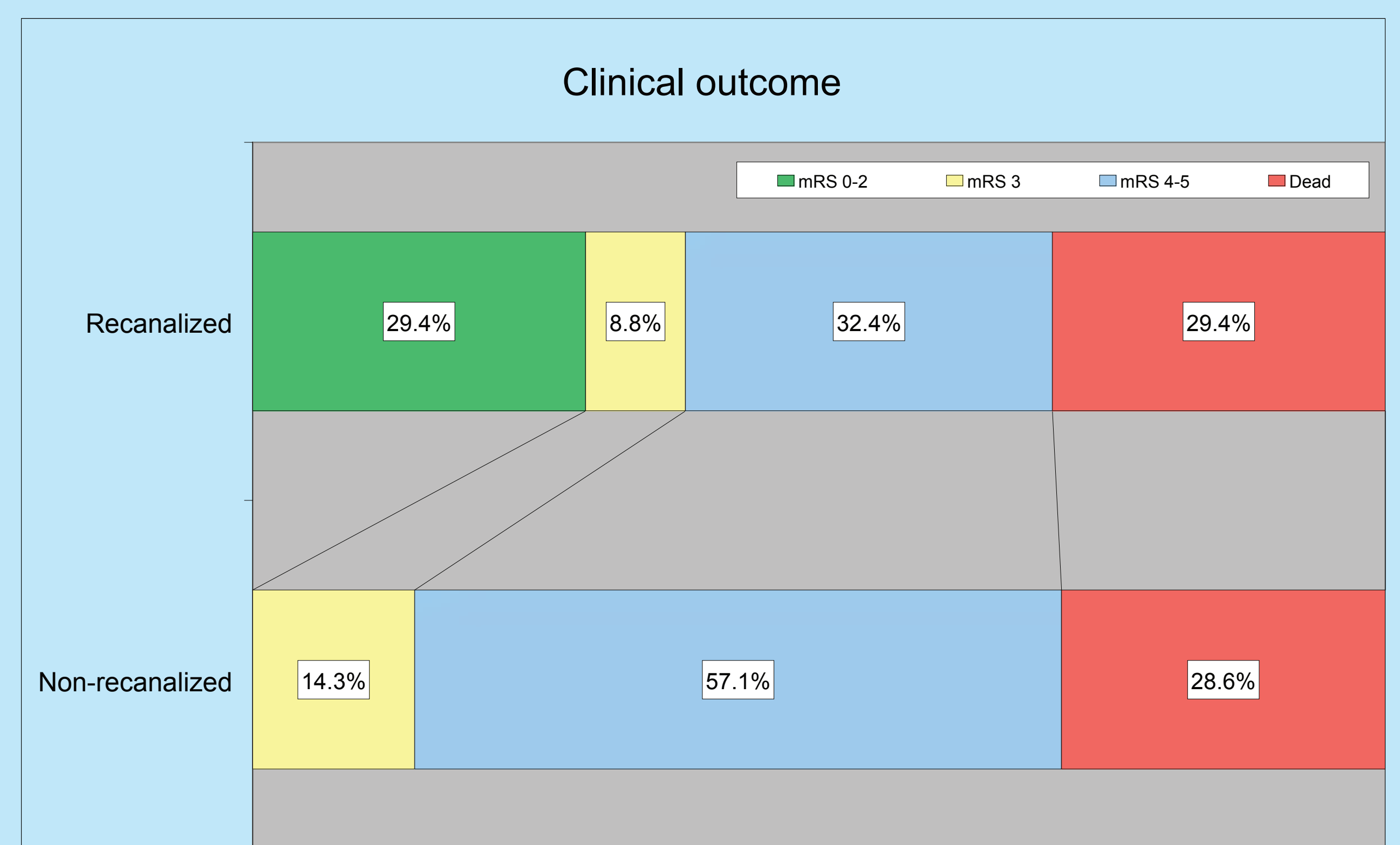
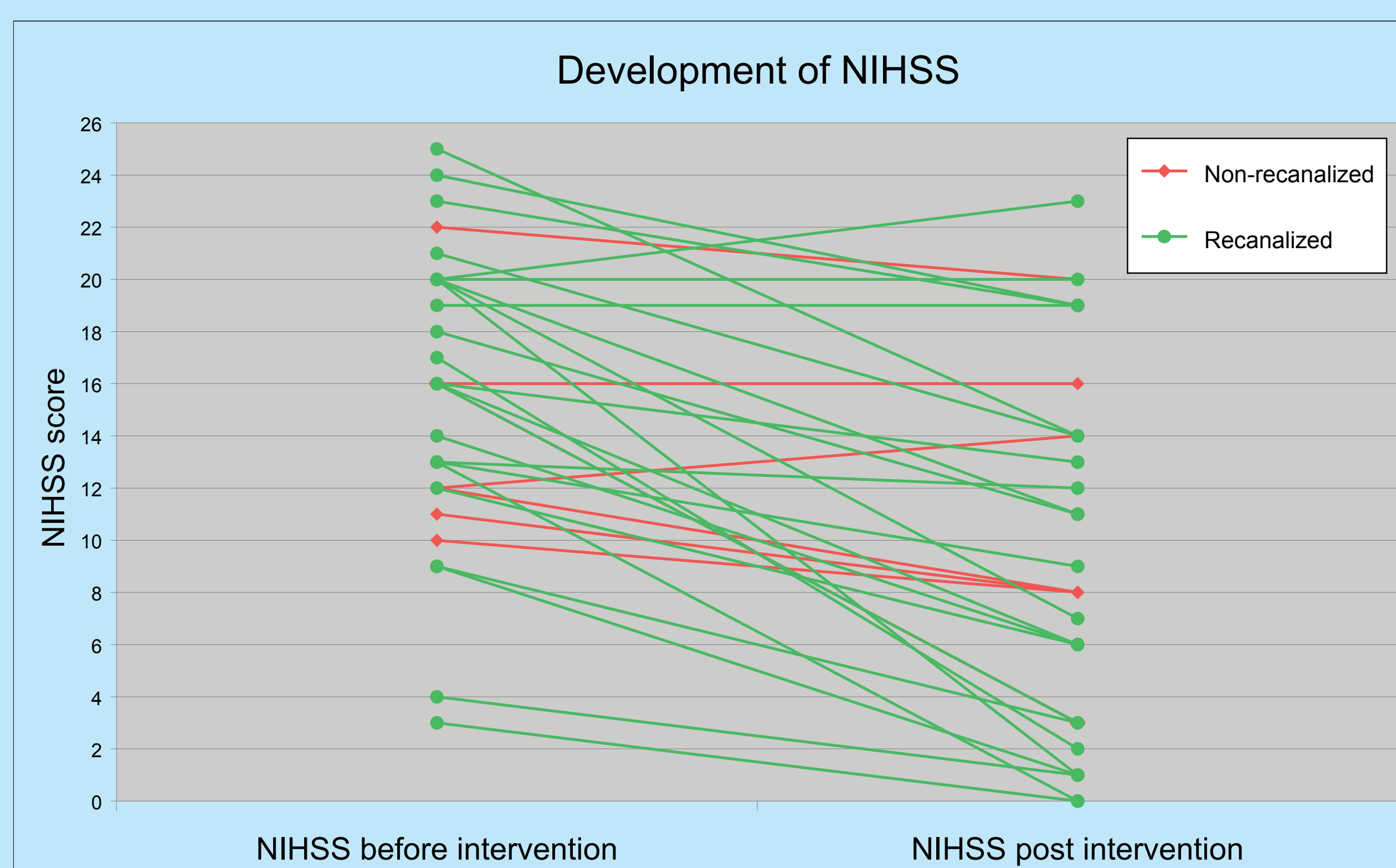
- CT scan after presentation → verified occlusion → iv thrombolysis (rt-PA) if eligible → angiography to exactly locate occlusion
- EMT → immediate angiographic control of results
- mechanical devices used for EMT → 1. stent retriever: Solitaire, Trevo, Preset, Separator; 2. other methods: Phenox Clot Retriever, Penumbra, Merci; 3. stents: Carotis Wall Stent, Wingspan Stent, Enterprise Stent
- procedure terminated after complete or partial recanalization (TICI score)
- CT scan 12 hours post EMT → ICH, infarction, bleeding into infarction
- symptomatic ICH = decline of ≥ 4 points on NIHSS score within 24 hrs
- Outcome measured with NIHSS (evaluated on presentation and discharge) and modified Rankin Scale (mRS) (evaluated at 3 months or post rehabilitation (redundancy letters); good: mRS 0-2, acceptable: mRS 3, poor: mRS 4-6

Results

| Variables | Overall (n = 51) | TICI 0-2a (n = 11) | TICI 2b-3 (n = 40) |
|--|-----------------------|----------------------|-----------------------|
| Age (years), median (SD, range) | 72 (SD 16.9, 23-94) | 80 (SD 14.3, 41-94) | 64.5 (SD 16.8, 23-90) |
| Female, n (%) | 26 (51%) | 6 (54.5%) | 20 (50%) |
| Time symptom onset to treatment (min), median (range) | 185.5 (80-404) | 180 (135-404) | 191 (80-355) |
| Time treatment to recanalization (min), median (range) | 81 (12-301) | 94 (34-219) | 68.5 (12-301) |
| Time symptom onset to recanalization (min), median (range) | 305 (121-498) | 376.5 (201-420) | 291 (121-498) |
| NIHSS on admission, mean (SD, range) | 17.05 (SD 5.76, 3-35) | 17.1 (SD 7.8, 10-35) | 17.03 (SD 5.26, 3-25) |
| NIHSS on discharge, mean (SD, range) | 9.3 (SD 6.72, 0-23) | 12.1 (SD 4.71, 8-20) | 8.6 (SD 7.02, 0-23) |
| NIHSS improvement > 4, n (%) * | 20/41 (48.8%) | 2/9 (22.2%) | 18/32 (56.2%) |
| NIHSS improvement > 10, n (%) * | 8/41 (19.5%) | 0/9 (0%) | 8/32 (25.0%) |
| Bridging rt-PA, n (%) | 33 (64.7%) | 6 (54.5%) | 27 (67.5%) |
| mRS after 90 days/ post rehabilitation | | | |
| Independent (mRS 0-2), n (%) * | 10/41 (24.4%) | 0/7 (0%) | 10/34 (29.4%) |
| Acceptable (mRS 0-3), n (%) * | 14/41 (34.1%) | 1/7 (14.3%) | 13/34 (38.2%) |
| Poor (mRS 4-6), n (%) * | 27/41 (65.9%) | 6/7 (85.7%) | 21/34 (61.8%) |
| 90 day mortality, n/n (%) | 12/41 (29.3%) | 2/7 (28.6%) | 10/34 (29.4%) |

* In case of missing data number of patients with data available are indicated as n/n.

- successful recanalization in 40/51 patients (78.4%) with mean mRS of 3.68 (range 0-6, SD 2.1)
- TICI 0-2a in 11 patients (21.6%), all of them had an unfavorable outcome of mean 4.43 mRS (range 3-6, SD 1.13)
- significance in age between patients with TICI 0-2a and TICI 2b/3 (p = 0,024, Mann-Whitney-U), patients with TICI 0-2a are older (median age 80 years) than patients with TICI 2b/3 results (median age 64.5 years)
- mortality in hospital 15.7% (n = 8), 2 (18.2%) with TICI 0-2a and 6 (15%) with TICI 2b/3
- mechanical devices used in EMT: 42 patients (82.4%) were solely treated with different stent retrievers and 9 patients (17.6%) with other devices
- procedure-related complications occurred in 12 patients (23.5%) such as SAB (n = 3), lost thrombi (n = 3), dissection (n = 2), perforation from micro-wire (n = 1) and tearing of stent (n = 1). ICH was seen in two patients and both were symptomatic (SICH, 3.9%).



Discussion / Conclusion

Despite a high rate of technical success (78.4% TICI 2b/3) the rate of favorable outcome post rehabilitation is relatively low (24.4% mRS 0-2). The outcome can be affected by different parameters such as age of patients, existence of collaterals, period of time from symptom onset to recanalization and NIHSS before the intervention. Good outcome and distinct improvement of NIHSS was only seen in patients with TICI 2b/3 which shows that EMT seems to be the right way. Compared to historical controls and conservative treatment a strong reduction of the mortality rate could be observed. Our data suggest that there are subgroups with quite different response to EMT. Crucial factors influencing outcome seem to be the time from symptom onset to recanalization, existence of collaterals and the quality of the recanalization result. How these factors are interacting regarding the clinical outcome of EMT should be the aim of future studies.

References

1. Jansen O, von Kummer R, Forsting M, Hacke W, Sartor K. Thrombolytic therapy in acute occlusion of the intracranial internal carotid artery bifurcation. AJNR. American journal of neuroradiology. 1995;16:1977-1986
2. Wunderlich MT, Stolz E, Seidel G, Postert T, Gahn G, Sliwka U et al. Conservative medical treatment and intravenous thrombolysis in acute stroke from carotid T occlusion. Cerebro vasc Dis. 2005;20:355-361
3. Bogousslavsky J, Regli F. Prognosis of symptomatic intracranial obstruction of internal carotid artery. European neurology. 1983;22:351-358
4. Georgiadis D, Oehler J, Schwarz S, Rousson V, Hartmann M, Schwab S. Does acute occlusion of the carotid t invariably have a poor outcome? Neurology. 2004;63:22-26
5. Wolpert SM, Bruckmann H, Greenlee R, Wechsler L, Pessin MS, del Zoppo GJ. Neuroradiologic evaluation of patients with acute stroke treated with recombinant tissue plasminogen activator. The rt-pa acute stroke study group. AJNR. American journal of neuroradiology. 1993;14:3-13
6. Beck C, Cheng B, Krutzmann A, Rosenkranz M, Gerloff C, Fiehler J et al. Outcome of MRI-based intravenous thrombolysis in carotid-T occlusion. Journal of neurology. 2012
7. Watanabe M, Mori T, Imai K, Izumoto H. Endovascular interventions for patients with serious symptoms caused by embolic carotid T occlusion. Neurologia medico-chirurgica. 2011;51:282-288

Acknowledgment

We are grateful to the participants and to the staff of the departments of neuroradiology and neurology of the Klinikum rechts der Isar, Technische Universität München. Thanks to Mr. Haller from the statistics department.